NEU Final
10th Batch

***We are not sure of the questions highlighted in yellow.**

SAQs:

SAQ Question 1:

1- A boy, half naked and in winter, was caught by the police walking alone at night. The police took him to the station, the boy reported that he has been hearing voices that are telling him that his family are plotting to kill him. He also reported seeing blood on the walls. When the police questioned him, he seemed as if he were talking to the sky. His family reported that he has been hearing sounds in the past year. His performance in school has been declining.

Question 1. Give three differential diagnosis:

1- Brief psychotic disorder
2- Schizophrenia
3- Schizophreniform

Question 2. Name two types of hallucinations that the patient was experiencing:

1. Visual
2. Auditory

Question 3. Name two symptoms that are required to diagnose a patient with schizophrenia. Give a brief explanation:

1-Hallucinations: seeing hearing and other experiences without an actual stimuli

2-Delusions: beliefs and thought that are not true

Question 4. What type of delusions was the patient experiencing?

- Persecutory delusions

Question 5. Give two drugs of choice:

1. Risperidone
2. Clozapine

Question 6. What is the definitive diagnosis

Schizophrenia

SAQ Question 2:

2-A patient with a history of atrial fibrillation and smoking presents to the ER 2 hours following sudden weakness on the right side of his body.

Question 1. What type of stroke did the patient have?

- Ischemic stroke

Question 2. Give a drug of choice, give its mechanism of action, and 2 contraindications for giving the drug. tPA. It is a fibrinolytic drug

contraindications:

1. Hemorrhagic stroke
2. If the symptoms lasted more than 4.5 hours

Question 3. Match the symptoms to the region of the brain affected and the corresponding artery

Loss of sensation on left leg and foot	Right Medial primary somatosensory area (BA1,2,3)	Anterior cerebral artery
Loss of right visual field with macular sparing	Primary visual area (BA 17)	Posterior cerebral artery
Loss of sensation of the entire left side	Primary sensory area (BA 1,2,3) thalamus	Middle cerebral artery and anterior cerebral artery
Dysphagia, dysarthria, loss of gag reflex, vertigo, and left sided ataxia	Left Lateral medulla	Left posterior inferior cerebellar artery

SAQ Question 3:

Patient presents with typical alzheimer's symptoms.

Question 1. Give 4 causes of cognitive and memory deterioration in this age group:

1. Lewy body dementia
2. Alzheimer's disease
3. Pick's disease
4. Vascular dementia

Question 2. Describe two feature in the following pictures:

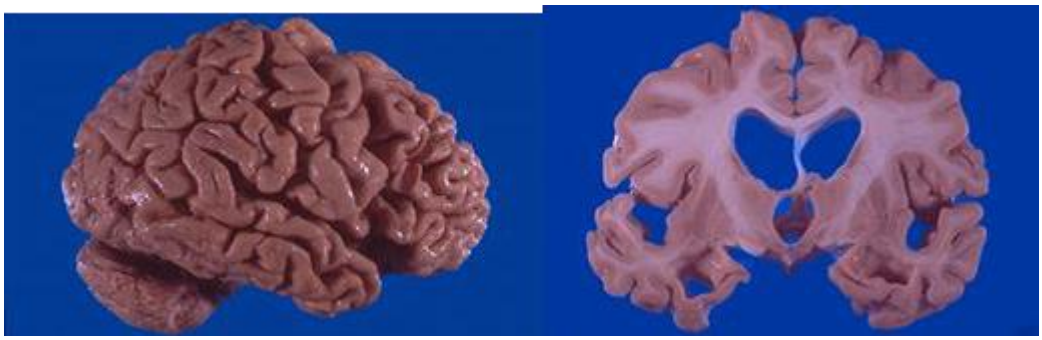

1. Atrophy of the frontal lobe
2. Bilaterally dilated ventricles (hydrocephalus ex vacuo)

Question 3. Describe the following histological findings:

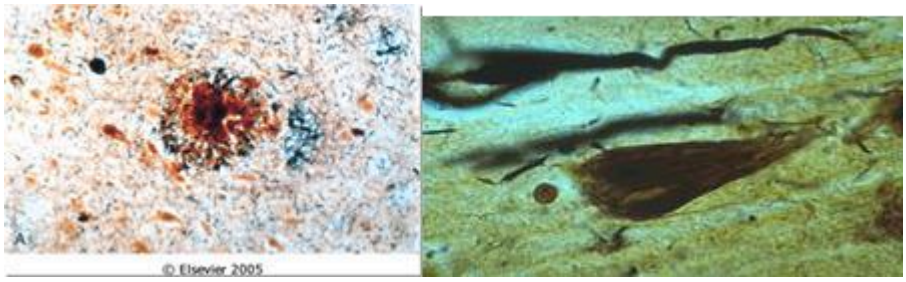

1. Neuritic plaques
2. Neurofibrillary tangles

Question 4. What is the most likely diagnosis?
Alzheimer's disease

Question 5. The patient was given memantine. What is the mechanism of action of the drug?
NMDA-receptor antagonist

SAQ Question 4:

A 2 year old came to your clinic with a non-pitting rash and fever.

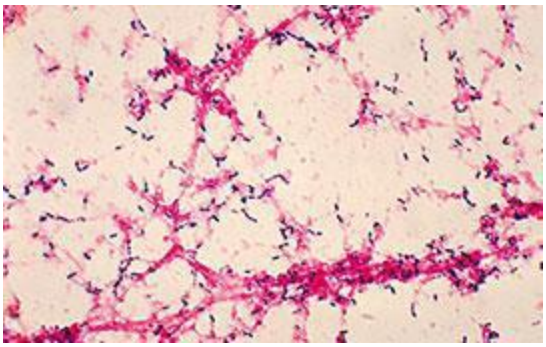

Question 1. What is the causative organism?
Streptococcus pneumonia

Question 2. Give a drug of choice and its mechanism of action Vancomycin.
Cell wall synthesis inhibitor

Question 3. What could you do to prevent this type of infection?
Vaccination

Question 4. When is lumbar puncture contraindicated?
Increased intracranial pressure

MCQs:

1) A 55-year-old right-handed women complained of acute onset headache and difficulty with vision. She quickly becomes unconscious on route to the hospital. She has a past medical history of hypertension. Her medications include aspirin and lisinopril at home. Her blood pressure is 150/90mm Hg and pulse is 90/min and regular. A stat head CT been without contrast demonstrates an acute hemorrhage in the left temporal lobe and compression of the anterior medial temporal lobe against the free margin of the tentorium cerebelli. Which of the following cranial nerves is most likely to be compromised in this patient?
    a) Optic
    b) Trochlear
    c) Abducent
    d) Oculomotor
    e) Trigeminal

Ans : D

2) A man comes to the ER with a wide gait, ataxic and slurred speech. His history reveals that he has been admitted into rehab for alcohol addiction three times in the past 5 years. He has also been arrested for drunk driven twice in the past year. His symptoms are most likely due to atrophy of which of the following :
    a) Frontal lobe
    b) Posterior vermis of the cerebellum
    c) Anterior vermis of the cerebellum
    d) Muscles of the lower limbs

Ans : C

3) A 23 year-old women is brought in by her husband to see a psychiatrist. He says the he often finds her talking to herself in the middle of the night, and sometimes even checking the house for implanted listening devices. And once when tried to give her sleeping pills so that she wouldn’t wake up in the middle of the night, she threw the glass of water and screamed that he was trying to poison

her. She also has been unable to concentrate in her studies and her grades have been declining. Which of the following is a negative symptoms in this patient ?

a) Talking to herself
b) Belief that her husband was trying to poison her
c) Unable to do well in her studies
d) Checking the house for listening devices

Ans: C

4) A 53 year old man with long standing schizophrenia has failed therapy with both first and second-generation antipsychotic agents. He still has significant problems with his mood, delusions and hallucinations. He is placed on clozapine. which of the following effects must the treating physician be aware of ?

a) Agranulocytosis
b) Cholelithiasis
c) Pancreatitis
d) Pituitary adenoma
e) Polycythemia

Ans: A

5) what is the most common bacteria that causes meningitis in neonate and elderly?

a) Streptococcus Agalactiae – Streptococcus Pneumonia
b) Staphylococcus Aureus – Enterobacteriaceae
c) Streptococcus Pneumonia – Streptococcus Agalactiae
d) Staphylococcus Epidermidis – Listeria Monocytogenes

Ans : A

6) A girl suffered from hallucinations. She was given an antipsychotic drug. The hallucinations were relieved but she is now suffering from extrapyramidal symptoms. Which drug has the highest risk for these symptoms?

a) Quetiapine
b) Clozapine
c) Risperidone
d) Iloperidone
e) Haloperidol

Ans : E

7) After reviewing Mr Tomas CT scan, the neurologist has advised the following cognitive test. Based on the patient presented symptomatology (see the attached picture) Which one of the following tests would you advise?

a) Wisconsin's sorting task.
b) Copy the picture
c) Go-No-Go task
d) False-Belief task
e) Word association task

Ans: B

8) A 10-year-old child fell from the roof top and MRI of the brain showed ischemia of bilateral temporal lobes due to extensive hemorrhages. Which one of the following behavioral changes is expected in this patient?

a) Docility
b) Excessive Anger
c) Excessive Fear
d) Excessive Sleepiness

e) Excessive Happiness

Ans : A

9) A 70-year old man developed stopped posture, masked facies, shuffling gait and pill rolling tremor in the right hand. Increased tonic discharge from which of the following structures is the cause of these symptoms?

a) Dentate nucleus
b) Globus pallidus interna
c) Putamen
d) Caudate nucleus
e) Thalamus

Ans: B

10) A woman presented to the ER with ptosis of the right eye lid, lateral strabismus, and spastic paralysis of the left side of the body. The woman most probably has a lesion in:

a) Right midbrain
b) Left midbrain
c) Right pons
d) Left pons
e) Right medulla

Ans: A

11) Meningitis caused by which of the following agents can be prevented by screening and administration of antibiotics to the pregnant woman at onset of labour?

a) group b streptococcus
b) Staphylococcus aureus

c) Neisseria meningitidis type b
d) Haemophilus influenzae
e) Cryptococcus neoformans

Ans : A

12) Which set of laboratory results from the CSF examination indicates a viral infection?

a) low opening pressure, normal glucose, abundant neutrophils.
b) high protein, high glucose, normal opening pressure
c) low glucose, turbid appearance, low opening pressure.
d) high protein, normal glucose abundant mononuclear cells
e) bands of oligoclonal antibodies and increased protein

Ans : D

13) a 61-year-old man has had a chronic cough for 6 years as a result of smoking 2 packs of cigarettes per day for 45 years. He has noted the onset of headache over the past 2 weeks. On neurologic exam there are no localizing sign. MR imaging of his brain has reveals 2-3 cm legions located mostly at the gray- white junction in the left frontal lobe. There is no ring enhancement. A stereotactic biopsy of this lesion is performed. Which of the following microscopic appearance is the most likely to be present in this biopsy?

a) bipolar astrocytes & Rosenthal fibers
b) Psammoma bodies
c) AV malformation
d) Multiple cysts containing brown fluid
e) Metastatic carcinoma

Ans: E

14) Which of the following nerves can be mistaken for C8 root compression?

a) Median
b) Musculoskeletal
c) Radial
d) Ulnar
e) Axillary

Ans: D

15) What is the mechanism of action of donepezil?

a) AChE inhibitor
b) Cholinergic blockade
c) Alpha-2 agonist

Ans: A

16) Which of the following is the most common cause of seizure in young adults?

a) Tumor
b) Stroke
c) Head trauma
d) Congenital
e) Febrile

Ans: C

17) What is the most common malignant tumor in children, that has the characteristic feature of Homer wright blue rosettes, and is specific to cerebellum?

a) Medulloblastoma
b) Ependymoma
c) Glioblastoma
d) Oligodendroglioma

e) Pilocytic Astrocytoma

Ans: A

18) Which of the following microbes can be seen with India/China Ink stain?

a) Cryprococcus neoformans
b) L. monocytogenes
c) S. aurues
d) N. meningitidis

Ans: A

19) A 65-year-old woman who fell to the ground and hit her head, is taken to the emergency department. Physical examination is unremarkable. CT scan of the head shows no hemorrhage fracture, but there is a 5cm mass beneath dura that compresses the underlying right parietal lobe.The mass is surgically removed. Histologic sections from the mass would most likely reveal:

a) Antoni A areas and Antoni B areas with Verocay bodies
b) Whorls of meningoepithelial cells and scattered psammoma bodies
c) Endothelial proliferation and nuclear pseudopalisading around necrotic area
d) Fried-egg appearance of tumor cells with scattered calcification
e) Sheets of anaplastic small blue cells with Homer-Wright rosettes

Ans: B

20) Parasympathetic innervation to lymph nodes can suppress the activity of immune cells by acting upon which of the following?

a) CREB
b) Nf-kB

Ans: B

21) What type of herniation is shown?

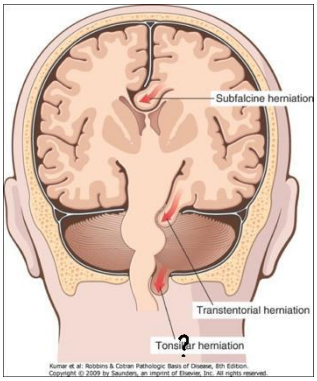

a) Subfalcine
b) Transtentorial
c) Tonsillar
d) Uncal

Ans: C

22) A female had loss of sensation in the leg and weakness in the hand . Few months ago, she had facial weakness. MRI showed the following image. What's the most likely diagnosis?

a) Multiple Myeloma
b) Multiple Sclerosis
c) Multiple Infarcts

Ans: B

23)A person was living in the retirement home, his family visited him and they noticed that he had no inhibition and he forgets what they just told him. When the nurse was asked, she said that he was normal and that he enjoys physical activity.What does he have ?

a) Alzheimer disease
b) Pick's disease
c) Parkinson disease
d) ALS

Ans: A

24) What measure should be applied on people who were in close contact with N. meningitidis carriers?

a) Give Rifampicin
b) Take a swab to check for N. meningitidis in culture
c) Ask the patient to stay home isolated

Ans: A

25) Which of the following genes is mutated in ALS?

a) APOE 4
b) SOD1

Ans: B

26) What medication should be avoided if the patient has narrow angle glaucoma?

a) Fluoxetine
b) Atomoxetine
c) Amitriptyline
d) Bupropion

Ans: C

27) Which of the following is the gold standard for diagnosing acute stroke?

a) Gadolinium enhanced CT
b) Non-contrast CT

c) Contrast CT
d) PET
e) Diffusion-weighted MRI

Ans: B

28) A patient presented to the clinic with hemiparesis after five hours from the onset. Non-contrast CT showed ischemic stroke. What's the next management?

a) IV heparin
b) tPA
c) Mechanical Thromboctomy

Ans: C

29) A patient was brought to the doctor by his family. He had increased appetite, loss of motivation, paranoia and conjunctival injection. What drug could cause these symptoms?

a) Alcohol
b) Marijuana
c) Cocaine

Ans: B

30) What's the duration for brief psychotic episode?

a) Less than one month
b) More than 6 months
c) 1-2 months
d) 4-6 months

Ans: A

31) Why do antidepressants take 3-6 weeks to show therapeutic effects?

a) Time for drug to reach steady state levels
b) Downregulation of autoreceptors

Ans: B

32) What is the most common cause of congenital non-communicating hydrocephalus?

a) Excessive CSF production
b) Blockage of foramen of Monro
c) Cerebral aqueduct stenosis
d) Arachnoid granulation disruption

Ans: C

33) Which of the following is associated with the shown picture?

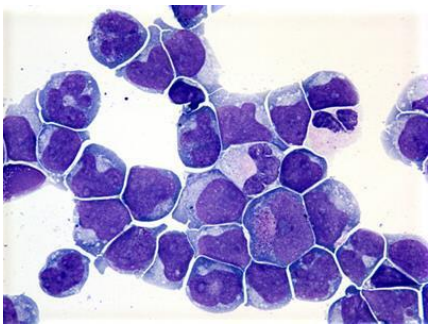

a) Herpes simplex
b) Neisseria meningitidis
c) Listeria monocytogenes
d) Mycobacterium tuberculosis

Ans: A

34) Patient after a stroke presented with loss of pain and temperature over the right side of the face and the left side of the body. Which of the following nuclei is responsible for this presentation?

a) Dorsal column + spinal trigeminal

b) Dorsal column tract
c) Lateral spinothalamic tract + dorsal column
d) Spinal trigeminal tract + spinothalamic tract

Ans: D

35) A patient opens his eyes in response to sound, he can localize the pain, his speech is incomprehensive. What score would you give him on a Glasgow coma scale?

a) 4
b) 8
c) 6
d) 12
e) 10

Ans: E

36) A 30 year old patient has a trouble going to sleep, so he would usually start to sleep in the morning which will affect his circadian rythm. How can you adjust his circadian rythm?

a) Use social cues
b) Giving him melatonin
c) give him antidepressants

Ans: B

37) Which of the following neurotransmitters/receptor will increase learning?

a) NMDA
b) AMPA
c) Ca++

d) Glutamate

Ans: A

38) A 22 year old male suffers massive trauma in a car accident. CT scan showed multiple intracerebral hemorrhages. He expired after 2 months. At autopsy, there were cystic spaces in parietal and frontal lobes. Which one of the following cells types resulted in formation of these cavities after clearing the hemorrhagic debris?

a) Astrocytes
b) Ependymal cells
c) Neuron
d) Oligodendrocytes
e) Microglia

Ans: E

39) A 28 year old man has a motor vehicle accident. He lost consciousness but then regained it and appeared normal to his friend. At later time in the same day he was confused and taken to the hospital. After two hours he died. Which of the following did the patient most had?

a) Epidural hematoma
b) Subdural hematoma
c) Subarachnoid hemorrhage
d) Intraparenchymal hemorrhage

Ans: A

40) A female suddenly discovered that she was pregnant although she has been taking oral contraceptives regularly for awhile. Two month ago she was diagnosed with having a complex partial seizure. Which of the following drug was she most likely taking that resulted in the pregnancy?

a) Amytriptyline
b) Carbamazepine
c) Valproic acid

Ans: B

41) When is the appropriate time to administer dexamethasone when treating meningitis in relation to antibiotics?

a) Administer dexamethasone starting 20 min before antibiotics
b) Administer dexamethasone starting 2 hours before antibiotics
c) Administer dexamethasone starting 1 hour before antibiotics
d) Administer dexamethasone starting 10 minutes after giving antibiotics

Ans: A

42) To which of the following can a patient who is taking opioid develop the least tolerance ?

a) Euphoria
b) Respiratory depression
c) Miosis
d) Nausea

Ans: C

43) What sequence is most sensitive for diagnosing acute ischemia?

a) T2 WI
b) Diffusion weighted imaging
c) FLAIR
d) Proton density
e) T1 WI post-Gadolinium

Ans: B

44) Which of the following has largest representation in the cerebral cortex ?

a) Hand
b) Neck
c) Leg
d) Toes

Ans : A

45) Communicating hydrocephalus is due to low absorption of CSF which is a result of tumor in which of the following:

a) Arachoroid villi
b) Sagital sinus
c) Tenturium cerebelli

Ans: A

46) A patient has symmetrical loss of sensation in his legs and feet. He also had ulceration in the leg. What is the most likely lab finding?

a) Elevated IgG
b) High creatinine kinase level
c) Leukocytosis
d) Blood glucose of 210 mg/dL (normal <200)

Ans: D

47) What occurs in partial seizures but not in generalized ?

a) Tonic

b) Clonic
c) Atonic
d) Myoclonic
e) Automatism

Ans: E

48) How can you induce a seizure in the clinic?
a) Hypoventilation
b) Hyperventilation
c) Hypoventilation + flashing lights
d) Hyperventilation + flashing lights

Ans: D

49) Patient is addicted to marijuana, and he is planning to stop. What should you tell him?
a) Taper the dose of marinole
b) Treat his anxiety
c) There is no pharmacological treatment

Ans: A

50) Patient suffering from left neglect syndrome which artery is affected?
a) Right middle cerebral artery
b) Left anterior cerebral artery
c) Right anterior cerebral artery
d) Left posterior cerebral artery
e) Left middle cerebral artery

Ans: A

51) Which of the following is true about GABA B receptors?

a) Ionotropic
b) Metabotropic
c) Induces depression and mood swings
d) Linked to Gq pathway
e) Produces EPSPs

Ans: B

52) Which of the following is true about the crossed extensor reflex?

a) It involves ipsilateral reflex arc
b) It involves contralateral reflex arc
c) Occur in the same side of the stimulus
d) It involves reciprocal stimulation

Ans: B

53) What's the mechanism of action of morphine?

a) Decrease K channels activation
b) Decrease Na channel inactivation
c) Increase NMDA-receptor activity
d) Decrease NMDA-receptor activity
e) Increase AMPA-receptor activity

Ans: D

54) What's it meant by the induction of anesthesia?

a) The onset of the anesthesia
b) The potency of the anesthetic

c) The efficacy of the anesthetic

Ans: A

55) A patient was staring for 20s. His EEG showed 3 Hz waves. What type of seizure does he have?

a) Myoclonic
b) Absence seizure
c) Simple partial
d) Complex partial

Ans: B

56) A patient had a stroke that manifested as loss of many motor functions on the right side. She wasn't able to speak. What is the most likely problem?

a) Wernicke
b) Broca
c) Dysarthria

Ans: B

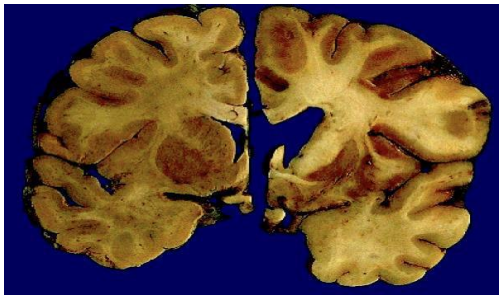

57) A section of the brain showed the following picture. What is the most likely scenario for this patient?

a) 40-year old male with fasciculation and spastic paralysis
b) Patient had abnormal movements and committed a suicide
c) A 70-year old had rigidity, facial mask, and tremor

Ans: B

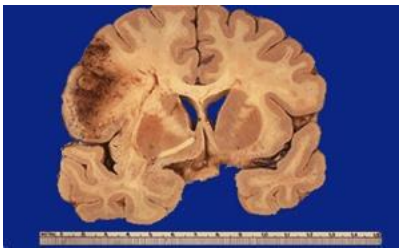

58) A patient had history of TIA. Brain section showed the following picture. What's the most likely cause?

a) Berry's aneurysm
b) Hypertension and renal failure
c) Mural heart disease
d) Rupture of AV malformation

Ans: C

59) A patient infected with DNA virus, and showed blisters on the lips. What's related to his infection?

a) Treated with acyclovir
b) Can be avoided by vaccine

Ans: A

60) Which of the following belongs to the descending pathway for modulation of nociception?

a) The periaqueductal grey that synapse on inferior olivary neurons then dorsal horn cells
b) The periaqueductal grey that synapse on neurons of the Raphe nuclei then dorsal horn cells
c) The periaqueductal that synapse directly on dorsal horn cells
d) Hypothalamus that synapse upon neurons of the nucleus solitarius then dorsal horn cells
e) Hypothalamus that synapse directly on dorsal horn neurons

Ans: B

61) What's the source of serotonin?

a) Raphe nucleus
b) Locus coeruleus

Ans: A

62) Someone who can't see but would still be able to sense a fearful stimuli through:

a) Thalamus
b) Hypothalamus
c) Prefrontal cortex

Ans: A

63) Which area is involved in impulsive disorders?

a) Orbitofrontal cortex

Ans: A

64) What is most common defense mechanism in patients with somatisation?

a) regression
b) Reaction formation
c) Denial

Ans: A

65) A patient manifesting heart disease symptoms even though all his tests were fine. What's the most likely diagnosis

a) Conversion disorder
b) SSD
c) IAD

Ans: B

66) A 10-year-old develop paralysis in his right lower limb after a viral illness. on examination, his right lower limb is flaccid, muscle mass significantly reduced as compared to the left lower limb. The knee and ankle reflexes are completely absent. Which of the following structures is affected in this case?

a) Anterior corticospinal tract
b) Lateral corticospinal tract
c) Anterior gray horn cells
d) Posterior gray horn cells
e) Lateral gray horn cells

Ans: C

67) In Huntington, there is increased tonic discharge of which of the following?

a) Subthalamic Nucleus
b) GPe
c) GPi
d) Substantia nigra

Ans: B

68) In Parkinson's, there is increased tonic discharge of which of the following?

a) a) Subthalamic Nucleus
b) GPe
c) GPi
d) Substantia nigra

Ans: C

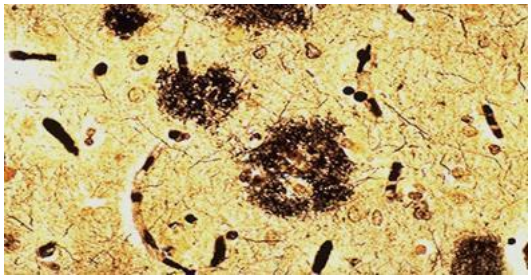

69) Which of the following is shown in the picture?

a) Neuritic plaque
b) Diffuse plaque
c) Neurofibrillary tangles
d) Alpha-synuclein

Ans: A

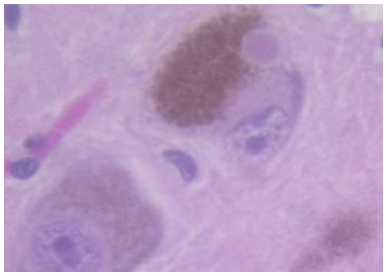

70) What's most likely to be found in this inclusions?

a) Lipofuscin
b) Alpha-synuclein
c) Melanin
d) Cowdry bodies

Ans: B

71) Which of the following is responsible for maintaining the posture and balance in the hip and in the shoulders?

a) Rubrospinal tract
b) Vestibulospinal tract
c) Tectospinal tract
d) Reticulospinal tract
e) Inferior Olivary tract

Ans: Most likely B

72) A patient presented with fever. MRI showed the following image. What's the most likely diagnosis?

a) Infarction
b) Hemorrhage
c) Brain abscess
d) Brain metastasis

Ans: C

73) One of the chronic complications of meningitis is the communicating type of hydrocephalus. It results from diminished absorption of CSF due to blockage in:

a) Pyramidal cells
b) Renshaw cells
c) Arachnoid villi
d) Purkinje cells
e) Sagittal sinus

Ans: C

74) A 66-year-old woman presented with the sudden onset of trouble walking. On examination she was weak in her right leg, with minimal hand weakness and no facial weakness. She spoke very little though she yelled at the hospital staff inappropriately, something that was out of character for her. She was also incontinent of urine. An occlusion of which of the following arteries can produce these symptoms?

a) Anterior cerebral
b) Anterior choroidal
c) Middle cerebral
d) Posterior cerebral

Ans: A

75) Which one of the following patients should be prescribed methadone - an abstinence medication?

a) A patient addicted to Cocaine
b) A patient addicted to Heroine
c) A patient addicted to Amphetamine
d) A patient addicted to hallucinogens
e) A patient addicted to Alcohol

Ans: B

76) Which of the following is the least used drug to maintain Parkinson disease?

a) Apomorphine
b) Saligiline
c) Amantadine
d) L-dopa

Ans: C or A (Not sure)

77) A female needed a local anesthesia for in vitro fertilization procedure. What should be used to give her a conscious sedation?

a) Midzolam
b) Diazepam
c) Lorazepam

Ans: A

78) Which of the following is used as an antidote for benzodiazepines?

a) Hydroxyzine
b) Buspirone
c) Flumazenil

d) Ramelteon

Ans: C

79) A patient has an epilepsy. And she was given an antiepileptic drug A. What's the most likely mechanism of drug A?

a) Increase the inactive state of Na channels
b) Increases Na channels permeability
c) Inhibits GABA receptors

Ans: A

80) A patient presented with headache for the last 3-4 years. It persists for 1 month every 3-4 month. He had periorbital pain. And there was increase lacrimal discharge. What's the most likely type of headache?

a) Sinus headache
b) Migraine
c) Cluster
d) Tension

Ans: C

81) A patient has a history of hypertension, cardiac problems, and angina pain. He presented with a headache and you wanted to give him a drug to relieve it. Which drug should not be used in this case?

a) Sumatriptan
b) Dihydroergotamine
c) Acetaminophen
d) Divalproex

Ans: B

82) What are the typical symptoms of Parkinsonism?

a) Bradykinesia, rigidity, tremor
b) Dance-like movement, headache, tremor
c) Hyperactivity, spasticity, facial mask
d) Akinesia, akathisia, athetosis

Ans: A

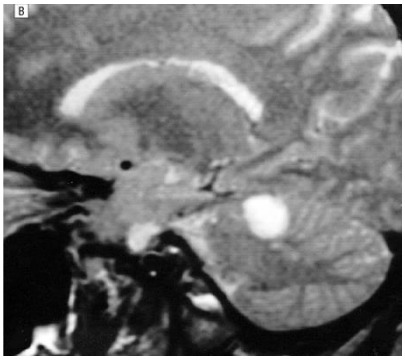

83) A patient presented with cerebellar ataxia, nystagmus, and abducens nerve palsy. An MRI given showed hyperintense region in the cerebellum. (A picture was attached showing infarction of the superior anterior region. We couldn't find the exact picture) Occlusion to which artery might have caused it?

a) PICA
b) Superior cerebellar artery
c) Middle cerebral artery
d) Anterior cerebral artery

Ans: A or B (Not sure)

OSPE:

Station 1:

A patient presented with ptosis of the right eyelid, lateral strabismus and loss of accommodation. He also presented with left hemiparesis of the body.

Which of the areas marked as A, B, C, D, E is involved in this case?

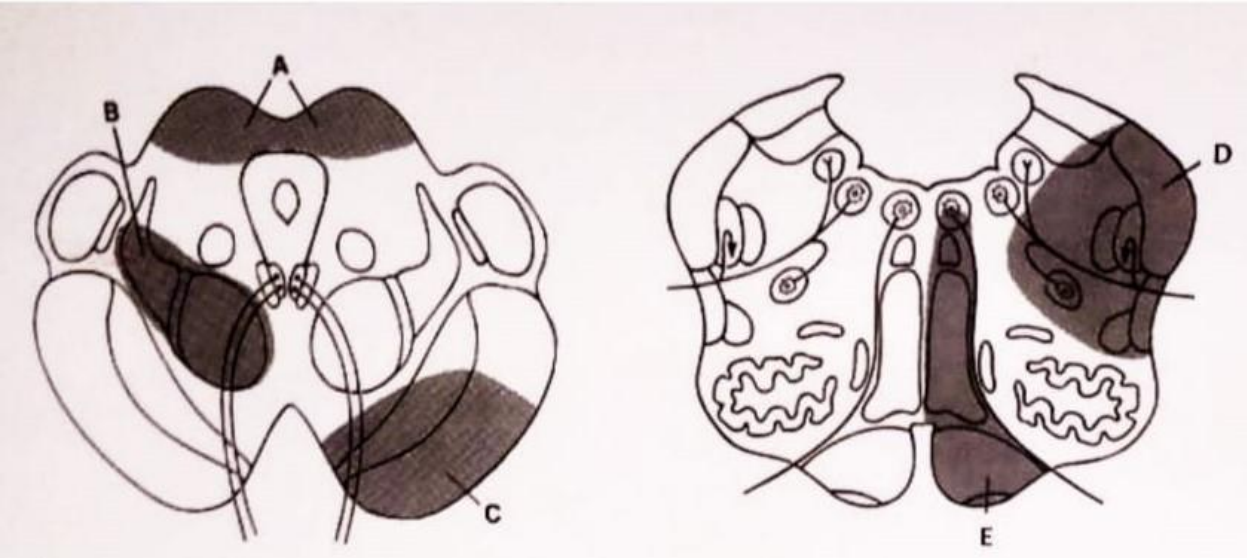

Ans: C

Station 2:

A 60-year-old man experiences tremors, bradykinesia, and festinating gait. Which of the structures marked in the picture has been degenerated in this patient?

Ans: D

Station 3:

An alcoholic with memory loss was diagnosed with Korsakoff syndrome. Identify the area involved:

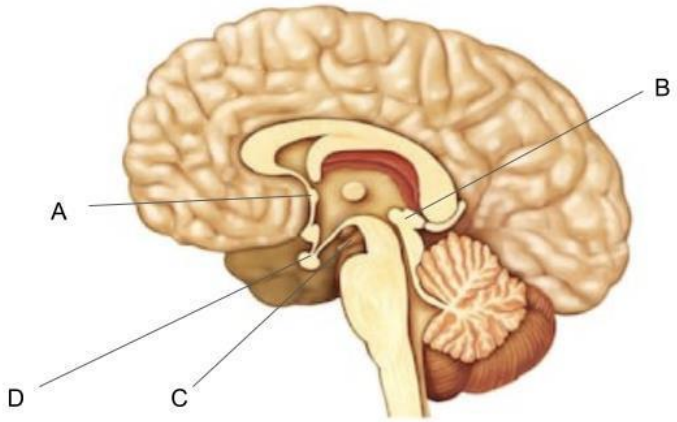

Ans: C

Station 4:

Identify the marked veins:

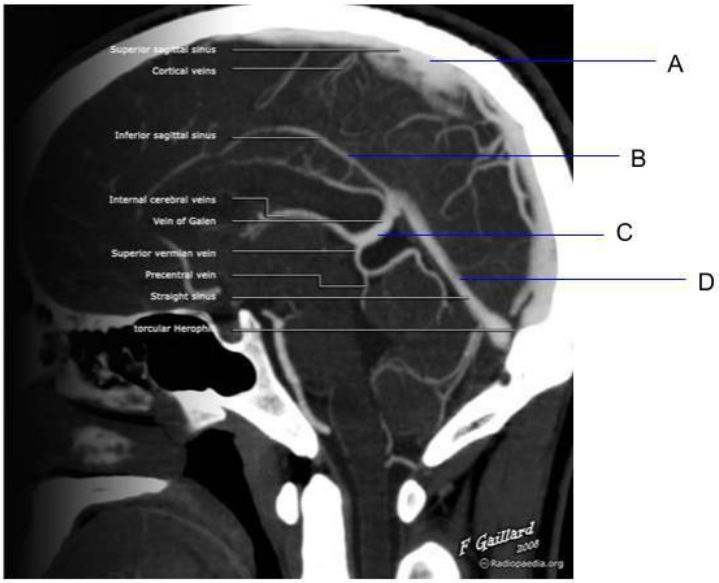

Ans:

A- Superior sagittal sinus

B- Inferior sagittal sinus

C- Vein of Galen/Great cerebral vein

D- Straight sinus

Station 5:

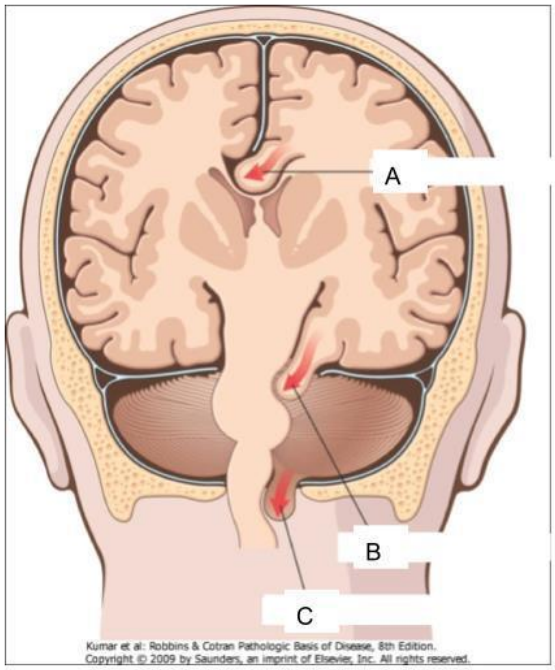

What is the type of herniation seen in C?

Ans: Tonsillar herniation

Station 6:

What is the embryological origin of the cell myelinating this structure?

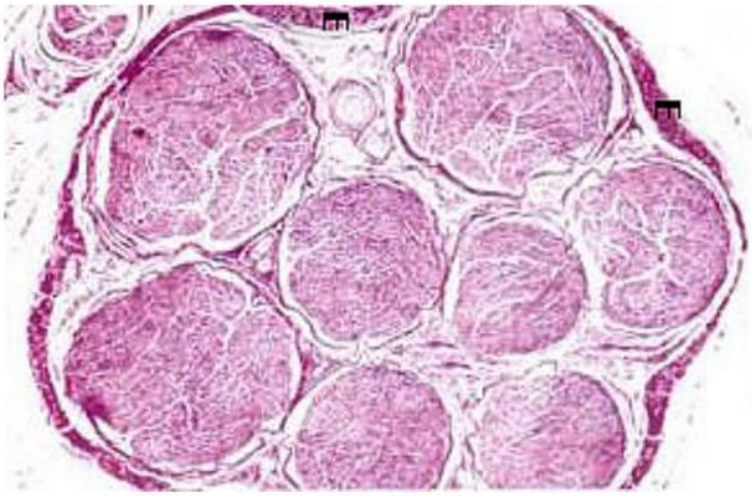

Ans: Neural crest cells

Station 7:

An 8-year-old girl fell from the roof and was brought in to the ER by her father. She showed signs of docility. Mark the area of brain affected.

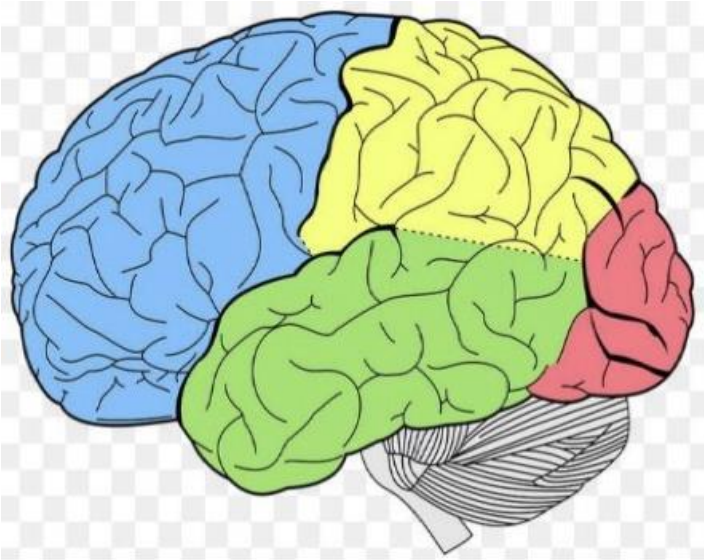

Ans: Inferior temporal lobe (the green one)

Station 8:

Which of the following cells is responsible for secondary motor functions?

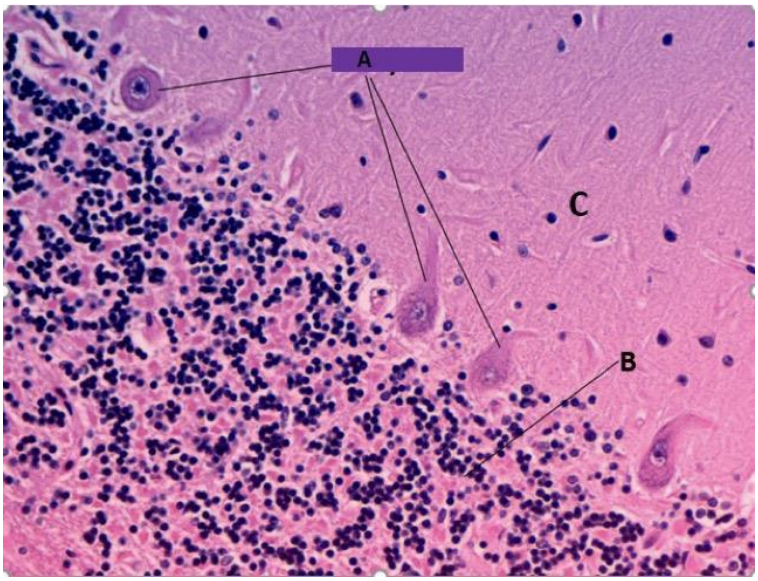

Ans: A - Purkinje cells of cerebellum

Station 9:

A medical student recorded his EEG waves in a relaxed, calm and quite laboratory setting while he was awake with his eyes closed. While recording he was asked to open his eyes, and was focused and alert, which of the EEG wave tracing frequency will diminish?



Ans: B

Station 10:

A patient presented with dropped face on the right, the injured nerve leaves the skull from which of the following foramena?

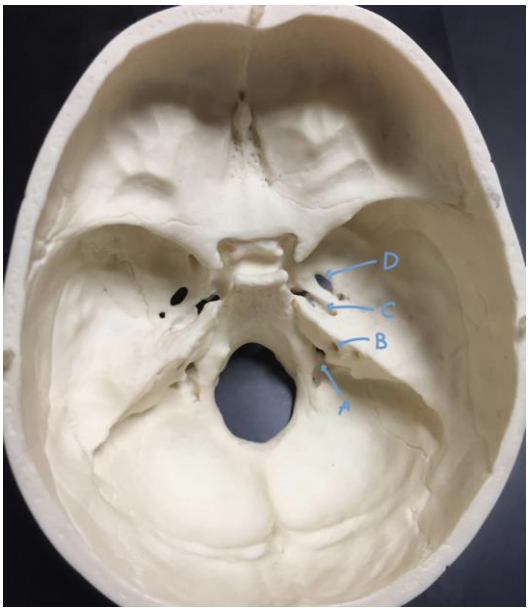

Ans: B, the internal acoustic meatus

Station 11:

A patient suffers from a penetrating knife injury at the T10 level on his right side. Which of the following images shows loss of pain and temperature on his body.

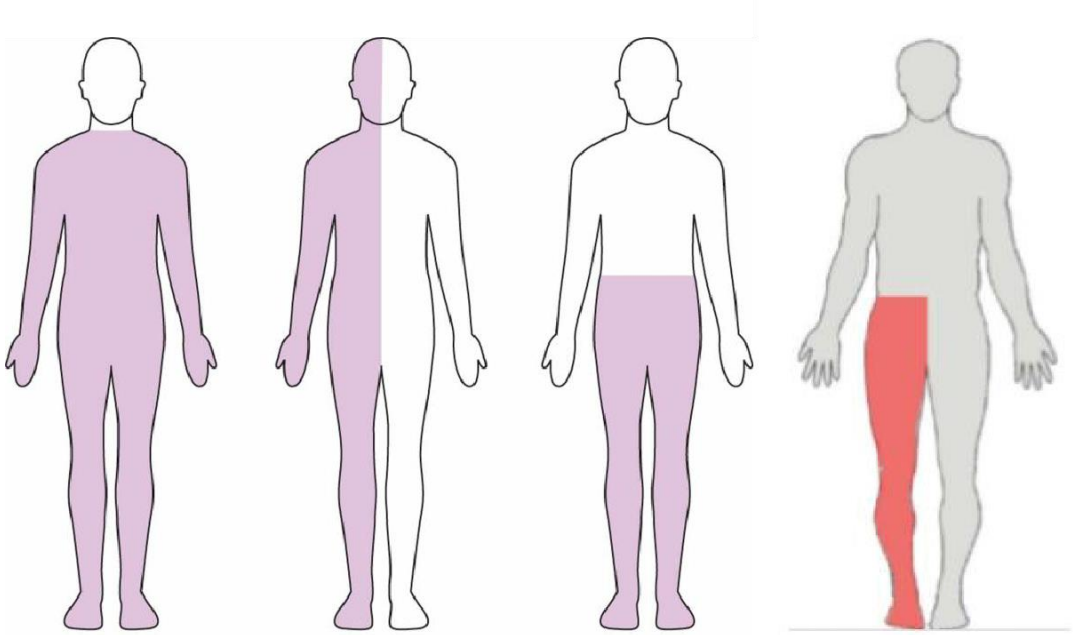

Ans: 1st pic on the right

Station 12:

Patient lost pain and temperature sensation from his left side of the face and right side of the body. She also has an unsteady gait and when she walks she falls to the left side. She also shows symptoms of dysarthria, dysphagia, and partial ptosis. Which of the arteries marked would most likely be affected?

Ans: 6 (PICA) -> (lateral medullary syndrome)

Station 13:

A patient who recently suffered from a stroke now presents with loss of sensory and motor loss over the lower left leg weakness. The upper limb shows full power. Mark the affected part of the cerebrum in the picture below.

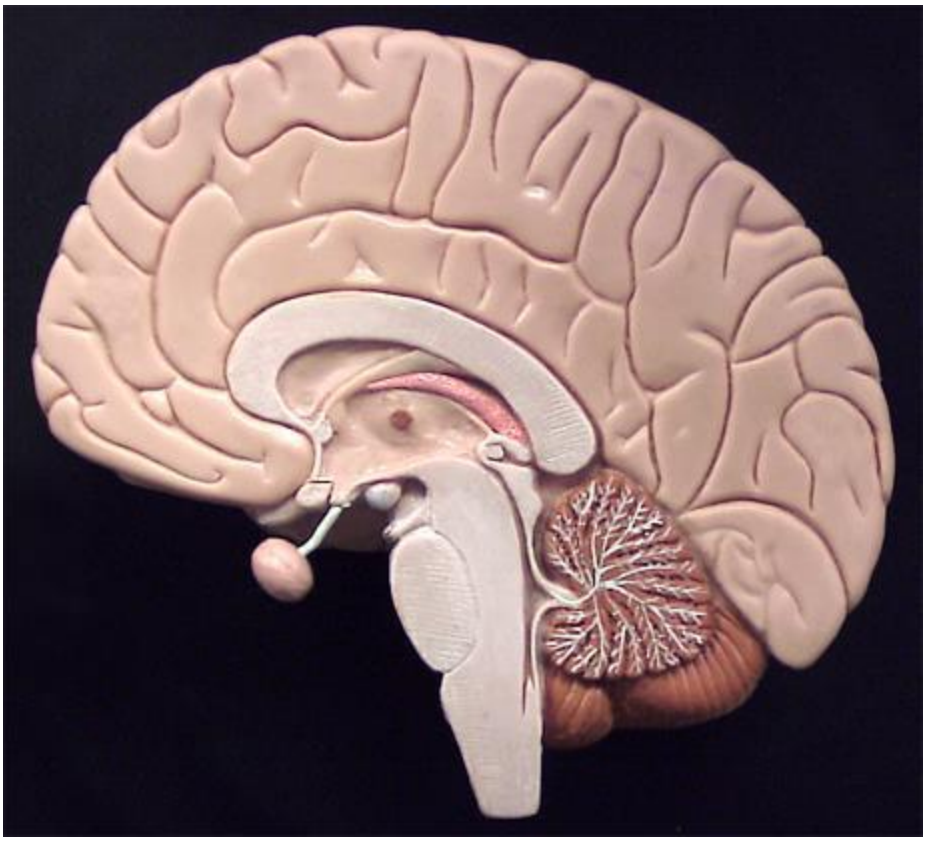

Ans: We put the pin somewhere around the central gyrus area

Station 14:

A) At what level does the structure shown in the MRI below end in infants?
B) Name two arteries that supply this structure.

The spinal cords ends at L3-L4 level
It receives blood supply from:
1) anterior spinal artery 2) posterior spinal arteries

Station 15:

Which letter indicates the latency period?

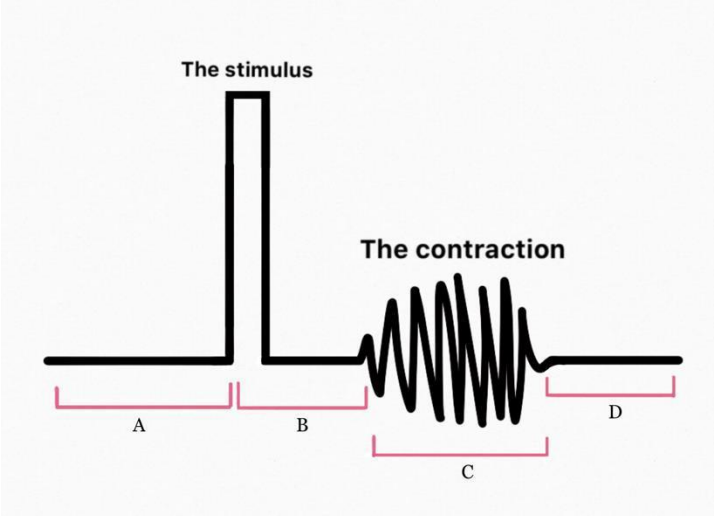

Ans: B

Station 16:

A doctor noticed that the patient has his head tilted to the right. Upon history taking the patient reported diplopia when looking straight and it was corrected by tilting his head to the right. Which cranial nerve marked as A B C or D in the model involved in this case?

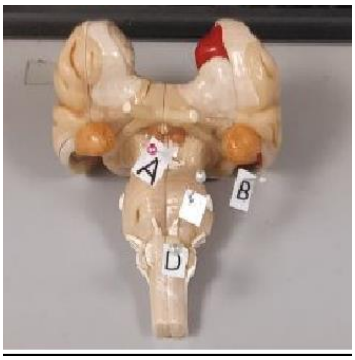

Ans: B

Station 17

A patient presented with contralateral spastic paralysis of half side of body with lower face involved, and contralateral loss of sensation of body. Mark the affected

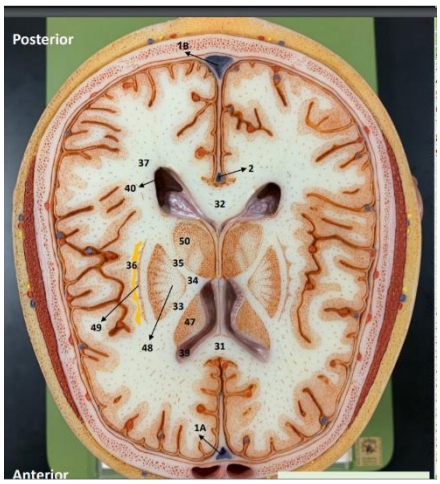

area in the provided cross section.

Ans: Posterior limb of internal capsule

Station 18

A patient had homonymous hemianopia with macular sparing.

A) Which area of the brain is affected?
B) What artery could be involved?

Ans:

A) The visual cortex in the occipital lobe
B) Posterior cerebral artery

Good luck :)